





ՀԻՐ
ԳՐԻՄԻՆ


Welcome

To the Joint Conference
in Uveitis and
Neuro-ophthalmology

JOUN 2022

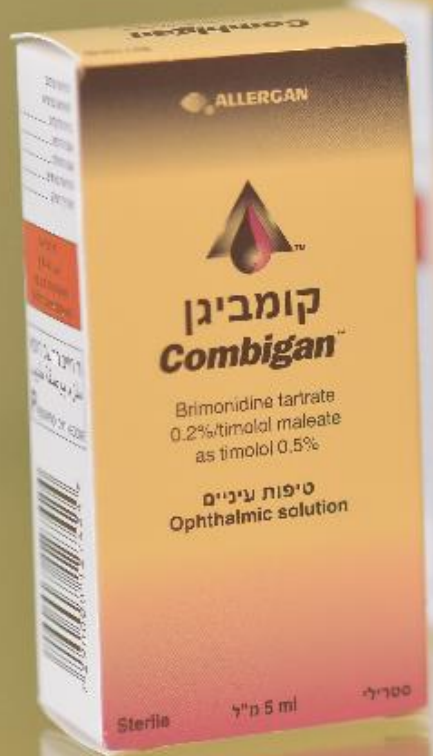24-26.3.2022

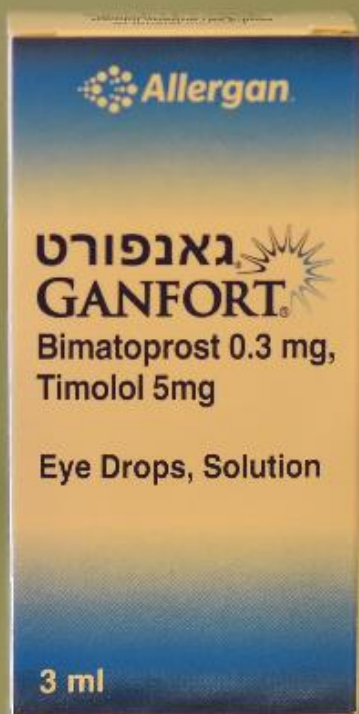Nazareth





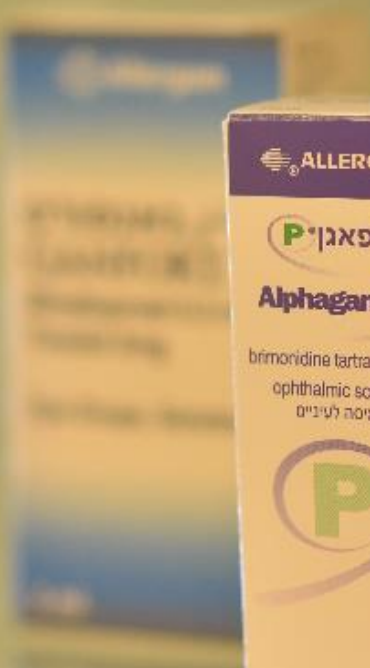




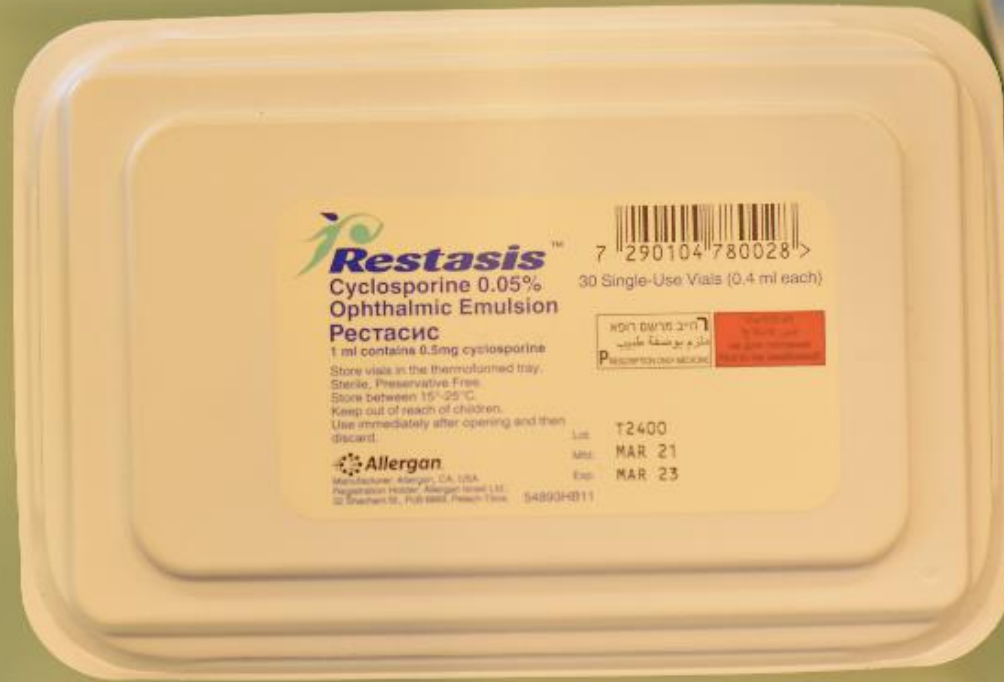
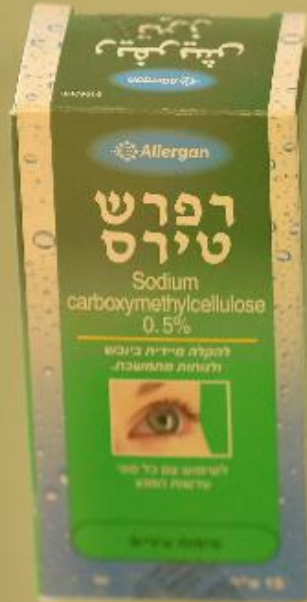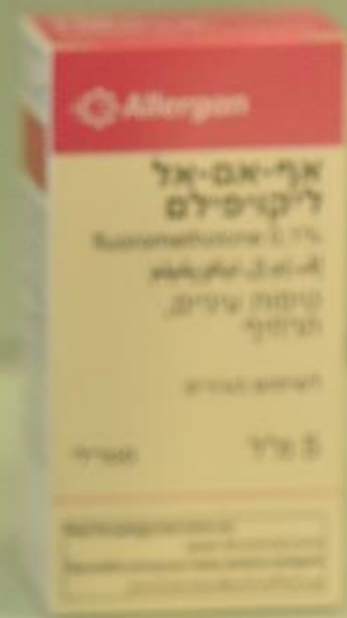
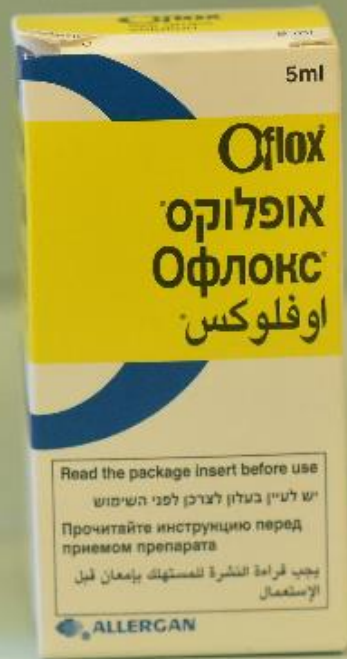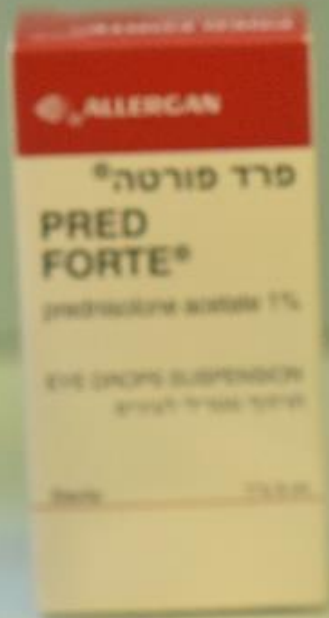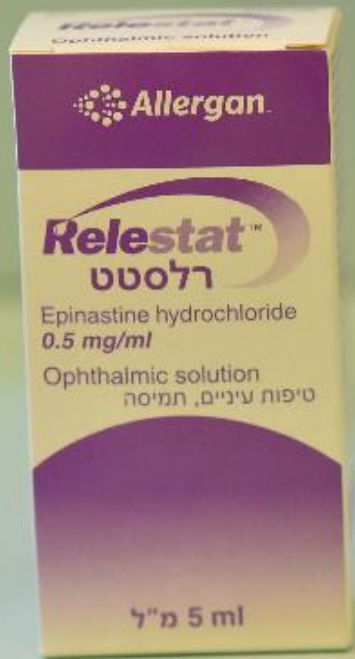3 ml





2LEBIFE 2 (4)







Three small boxes of medicine on the top shelf. The middle box is labeled "CANTHAR" and the right box is labeled "PAIN".

Three boxes of medicine on the middle shelf. The left box is green, the middle box is white, and the right box is blue.

Four boxes of medicine on the bottom shelf. The boxes are purple, white, yellow, and white.

Ozurdex[®]
(dexamethasone intravitreal
implant) 0.7mg



Timing is everything

WHY TIMING IS CRUCIAL?



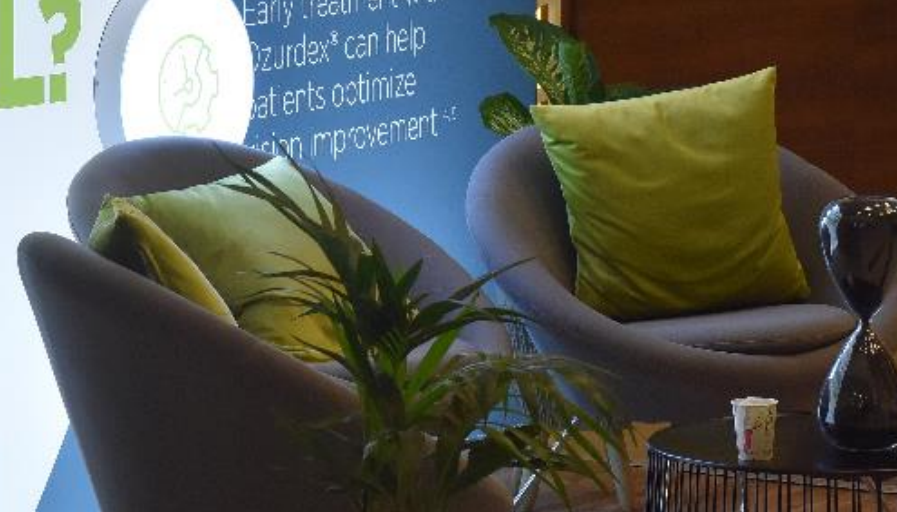1/3rd of DME patients
were insufficient
responders^{1,2}



Chronic macular
edema may lead to
irreversible changes
in the retina³



Early treatment with
Ozurdex[®] can help
patients optimize
vision improvement^{4,5}



Ozurdex[®]
(dexamethasone intravitreal
implant) 0.7mg



Timing is everything

**WHY
TIMING IS
CRUCIAL?**



1/3rd of DME patients
are insufficient
responders^{1,2}



Chronic macular

...may
be reversible
if the retina



Early treatment
Ozurdex[®] can be

DAY 1-MARCH 24th 2022





Ella Azulay
Novartis

Oxana Kuzmin
Novartis

Adi Berger
Novartis

Oshrat Raz
Novartis

WHY TIMING IS CRUCIAL

Chronic macular edema may lead to irreversible changes in the retina³

Early treatment with Ozurdex[®] can help patients optimize vision improvement

1. Busch et al. *Acta Diabetol.* 2018;55(8):785-790.
2. DRCRN. *Ophthalmology* 2010;117:1064-1071.
3. Ranchood & Fine. *Clin Interv Aging* 2009;4:1-10.
4. Udeondo et al. Presented at the American Academy of Ophthalmology, 2018.
5. Escobar-Barranco et al. *Ophthalmologica* 2018;242:1-10.








Welcome

To the Joint Conference
in Uveitis and
Neuro-ophthalmology

JOUN 2022

24-26.3.2022
Nazareth



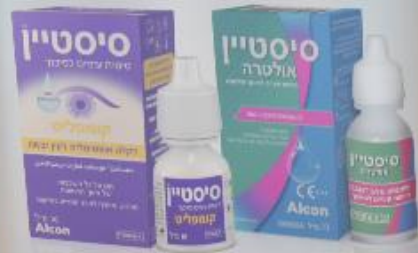







העין יבשה?
סיסטיין בבקשה!



#1

לטיפול ביובש בעיניים
נחת ביותר בישראל!

העין יבשה?
סיסטיין בבקשה!



#1

הטיפול לטיפול ביובש בעיניים
הנמכרות ביותר בישראל!



























VA 6/7.5, resumed [unclear] with dose adaptation → stopped MTX d
[unclear] stable on low dose topical steroids.
[unclear] on oral disease-modifying medications

MAG

na medications

























- Exceptions exist

Otherwise normal neuroradi

- Except for signs of increased I

other cause of increased

MAC

DA
RETH



○ D/C after 2.10 years due to

○ Current Tx: **azathioprine 150**

○ Both started when MTX wa

MAG

consequences are severe³

1. Heiligenhaus A et al. Uveitis in juvenile idiopathic arthritis. *Dtsch*
2. Heiligenhaus A, et al . Prevalence and complications of uveitis in
tion of the current screening guidelines. *Rheumatolog*
3. Heiligenhaus A et al . Review of the year: epidemiology of juve
2013;21:180-191

MAC



1. Heiligenh
2. Heiligenh
modificat
3. Heiligenh
Inflamm.

4=agree completely)

* In most questions, there was no statistical difference between the JIA group and the JIA-uveitis group











...treatment options in HADS...

...commercially available...

...is sponsored by...

M2





























SOURASKY
CENTER

Tel Aviv Unive

MA









Percentage

Publ

Se

Syn

906,197

27

937,116

10

913,091

36

823,068

126

921,121

26

933,217

26

775,261

411

MAG

Oren Tassini-Hetzer
Moderator/Co-Editor





















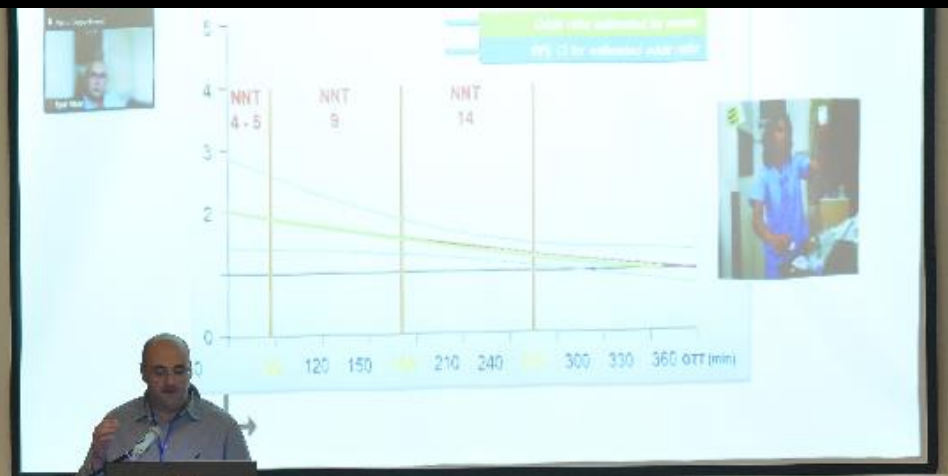
DAY 2-MARCH 25th 2022



cell dysfunction

47 y-o female homocystinuria and aphasic. NHSS 18

MAC




Speaker at podium



Hadassah Medical Center























• 2015: Pulmonary embolism

MAG

www.venmar.com

www.magnat.com

TRAVEL

GOOD THINGS HAPPEN FOR OTHER PEOPLE.

Thank you!
Questions?

www.drshimodotan.com



RAMADA





















250mg x2/d
phagan, xalatan, sterodex x8/d

































DAY 3-MARCH 26th 2022









Based on



















































10	F	48.3	00	00	013	00	013	04
11	F	28.5	00	00	00	00	00	00
12	M	29.2	00	00	00	00	00	00
13	M	40.0	00	00	00	00	00	00
14	M	52.6	00	00	00	00	00	00









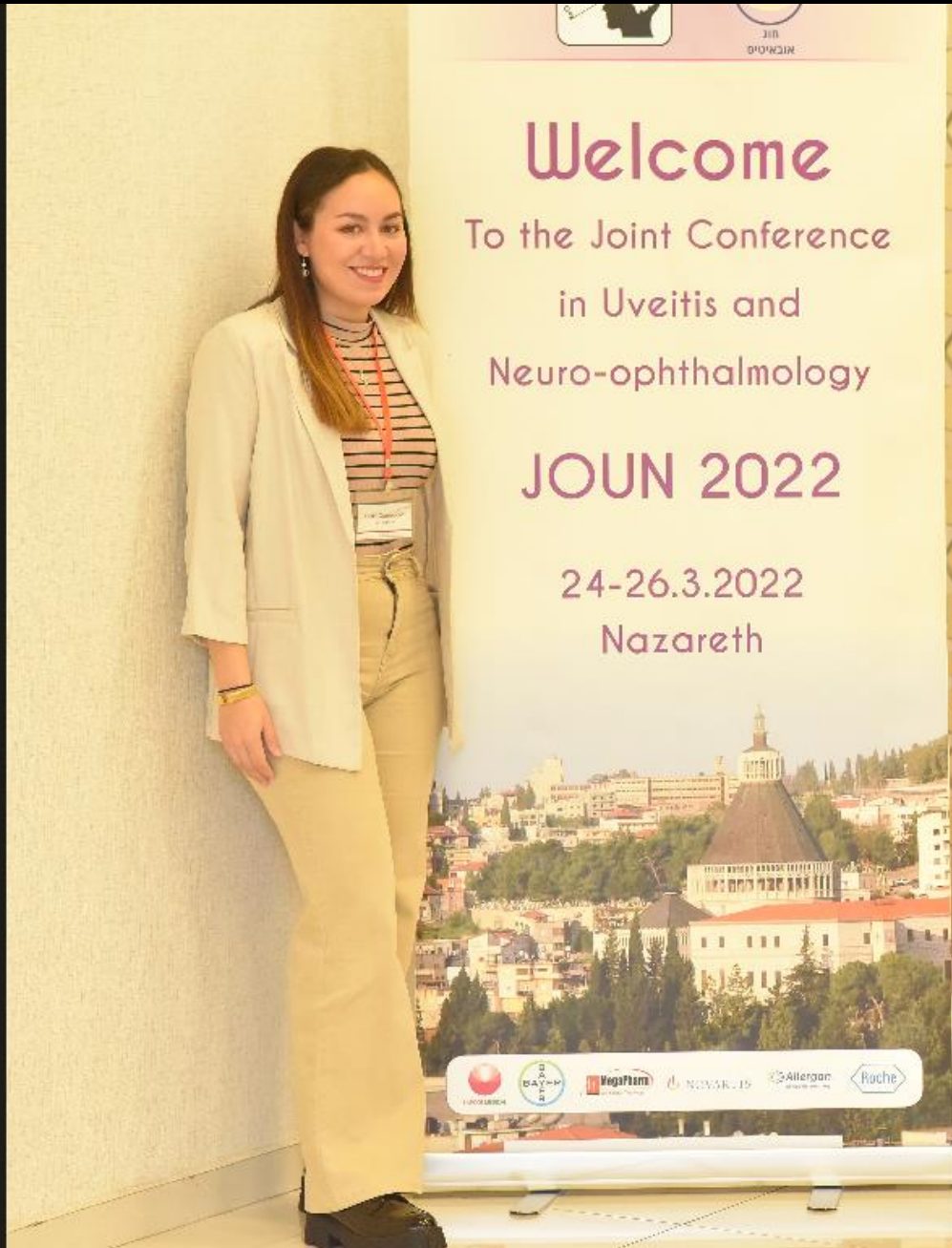


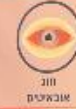










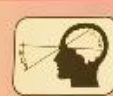Welcome

To the Joint Conference
in Uveitis and
Neuro-ophthalmology

JOUN 2022

24-26.3.2022
Nazareth





MICRONA

Welcome

To the Joint Conference
in Uveitis and
Oculo-ophthalmology

BOUN 2022

24-26.3.2022
Nazareth













VE Retinopathy with significant vitreous involvement

neoplasia, active TB and sarcoidosis

Ocular oncology
The Goldschleger Eye Institute
Sheba Medical Center
Tel Aviv University











JOUN 2022
Kare, 24th - 28th
Nazareth

Certificate of Best Presentation
Presentation

Nimer Sayed Ahmad
of the Unit, Conference in Nazareth, 24-28 June 2022

Senior Advisor

Hanan Jabbal Habbal
Chairwoman
Nazareth University, Campus

Rafiq Khatib
Chairman
Nazareth University, Campus



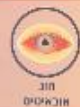











Welcome

To the Joint Conference
in Uveitis and
Neuro-ophthalmology

JOUN 2022

24-26.3.2022
Nazareth

